

Preclinical *In Vivo* Imaging

## Authors:

Jen-Chieh Tseng, Ph.D.

Ali Behrooz, Ph.D.

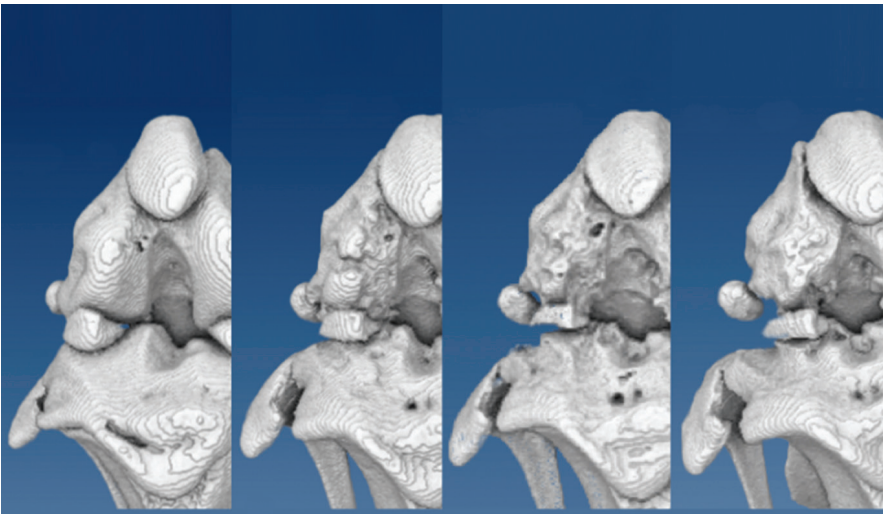
Jeff Meganck, Ph.D.

Josh Kempner, Ph.D.

Jeffrey D. Peterson, Ph.D.

PerkinElmer, Inc.

Hopkinton, MA



## MicroCT Investigation of Bone Erosion and Deformation in an Osteoarthritic Rat Model

### Abstract

The Quantum GX is a cutting-edge non-invasive imaging system that represents the latest advances in microCT technology

in resolution, speed, and data visualization. This versatile preclinical imaging system is proven for a broad range of applications in pulmonary disease, cardiovascular disease, diabetes, orthopedics, cancer, and dentistry, with a range of animal capabilities from mice and rats to guinea pigs and rabbits. This Application Note will discuss the use of the Quantum GX imaging system to investigate and monitor longitudinal bone erosion in an osteoarthritis (OA) using the standard imaging software that is included with the system and PerkinElmer's AccuCT™ advanced automated bone analysis software.

OA is the most common form of arthritis and affects a considerable portion of the elderly population. In the U.S., it is estimated that 27 million Americans have this chronic condition, generally in the knees. OA occurs when the cartilage that cushions the ends of bones within the joints gradually deteriorates, causing synovitis and joint deformation. The progressive bone degradation that occurs in OA makes it ideal for visualization of disease development using microCT.

Many aspects of this human condition can be established in laboratory rats by injection of monosodium iodoacetate (MIA) into the intra-articular space of the knees. After MIA injection, we performed longitudinal microCT imaging for up to 6 weeks. Standard scans allow the simultaneous capture of bone images for both the affected and contralateral knees, and the higher resolution images for each joint can be generated by subsequent sub-volume reconstruction of the same dataset for accurate volumetric measurement. Volumetric analysis of bone erosion associated with this disease model was performed and visualized using the standard bone analysis software. Subsequently, the image data sets were analyzed using AccuCT advanced bone analysis software. This software can automatically identify and mask bone objects from the CT data set generated by the Quantum GX and is capable of automatic segmentation of the affected bones, an advancement that greatly facilitates the ease, speed and reproducibility of the analysis. With minimal human involvement, the segmentation results are more consistent and accurate by eliminating the need for frame-by-frame review of the CT data during the object masking process.

## MicroCT Imaging of Osteoarthritis in Rats: Model, Method and Data Processing

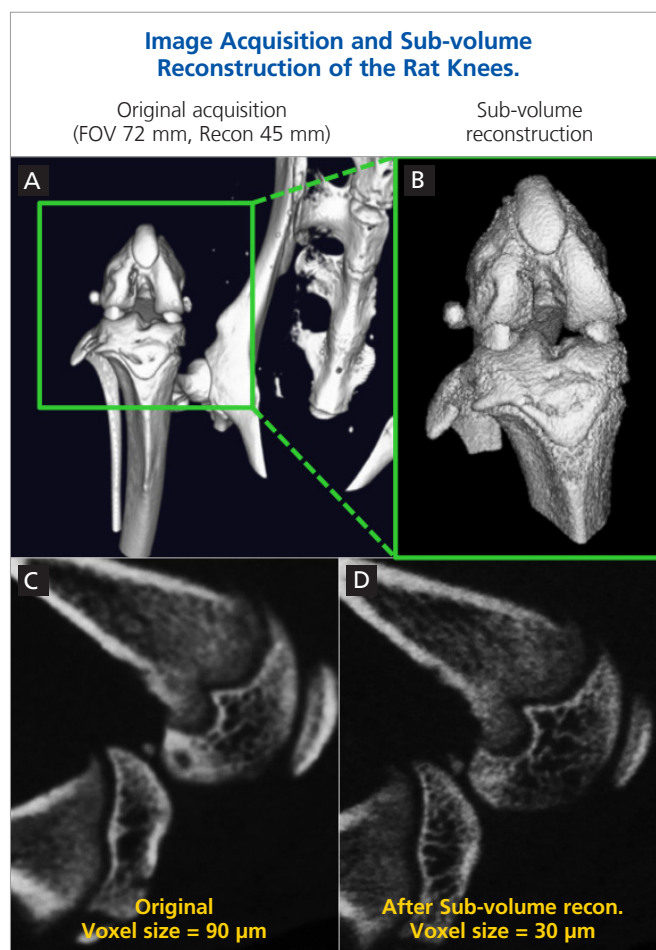
To facilitate translational research of this condition and treatment development, several clinically-relevant animal models have been developed. In particular, a rat model has been well established by intra-articular injection of monosodium iodoacetate (MIA) into the knee in order to trigger synovial inflammation and osteoarthritis in the joints.<sup>1,2</sup> For the microCT imaging study, 3 mg of MIA in 50  $\mu$ L sterile 0.9% saline was injected through the patellar tendon and into the knee joint cavity of anesthetized CD rats.

For knee imaging, the Quantum GX microCT imaging system has a unique feature that allows the users to enhance the image quality of a previously acquired microCT image by performing a sub-volume reconstruction of a selected sub-region of the raw image data. For this study, the original acquisition used a large field of view (FOV = 72 mm, Recon 45 mm, standard 2 min scan time) to capture the lower torso and right leg of rats (Figure 1A). The original image data was then subjected to sub-volume reconstruction using the Quantum GX software interface (Figure 1B). In this case, we were able to enhance overall image quality by reducing voxel size from 90 to 30 microns (Figure 1C and D). This feature eliminates the need for repeated imaging of the same region of interest in order to obtain high resolution images, thus reducing both imaging time and ionizing radiation dose to the animals throughout a longitudinal study. Furthermore, the smaller voxel size of the secondary reconstruction improves the 3D rendering details and facilitates more accurate volumetric measurements.

Figure 2 summarizes the microCT 2D slice images of the joint after MIA injection. These images were acquired as previously described in Figure 1. The week 0 reference images represent the normal knee joint before the MIA injection, when no visible bone erosion or joint damage was observed. Using a standard image visualization software, the femoral and tibial epiphyses were represented with different colors for visual presentation and identification. As early as two weeks after MIA injection, although there are no obvious clinical signs of disease, the high-resolution microCT images generated by the Quantum GX system captured the subtle onset of bone erosion on the surface of epiphyses. By week 6, the microCT images revealed substantial joint deformation which closely mimics the development of osteoarthritis in humans.

### 3D Visualization of Bone Erosion in the MIA Osteoarthritis Model

In the previous section, Figure 2 demonstrated the use of high-resolution 2D slices of Quantum GX microCT data to detect subtle changes during disease progress. The microCT dataset can also be viewed in 3D for a more comprehensive view of bone surface erosion and for subsequent quantitative analysis of the affected joints. The visualization software provided as an



**Figure 1:** In this study, the rat knees were imaged on the Quantum GX microCT system with a standard 2 min scan which entails a physical FOV of 72 mm and a software reconstruction of 45 mm. (A) Image of a normal rat knee. After acquisition, the 3D image was reconstructed using the standard Quantum GX system acquisition software. Subsequently, a smaller region of interest (ROI, green box) was selected for further sub-volume reconstruction. (B) The sub-volume reconstruction provides a more detailed view of the region of interest (knee bones). (C and D) 2D slice views of the knee before (C) and after sub-volume reconstruction (D). The sub-volume reconstruction procedure enhanced image quality and detail by reducing image voxel size from 90 to 30 microns.

option with the Quantum GX can be used to manually segment bones of interest and assign pseudocolors for visualization. The segmentation process involves careful review of each 2D image frame in the image stack to identify the target areas. To facilitate the process, the software provides several tools such as the Wall tool and Separation tool to help the users identify and separate different 3D bone segments. Nevertheless, in order to obtain accurate 3D objects, it typically requires careful manual review of each frame in the target region.

Figure 3 summarizes the 3D segmentation images of the epiphyses after MIA injection. The 3D renderings clearly demonstrate widespread bone erosion and destruction as a result of MIA injection. Within two weeks after MIA injection, pitting on the epiphysis bones surface was evident, which gradually progressed to more severe bone deformation by week 6.

### Bone and Joint Destruction in MIA Osteoarthritis Model

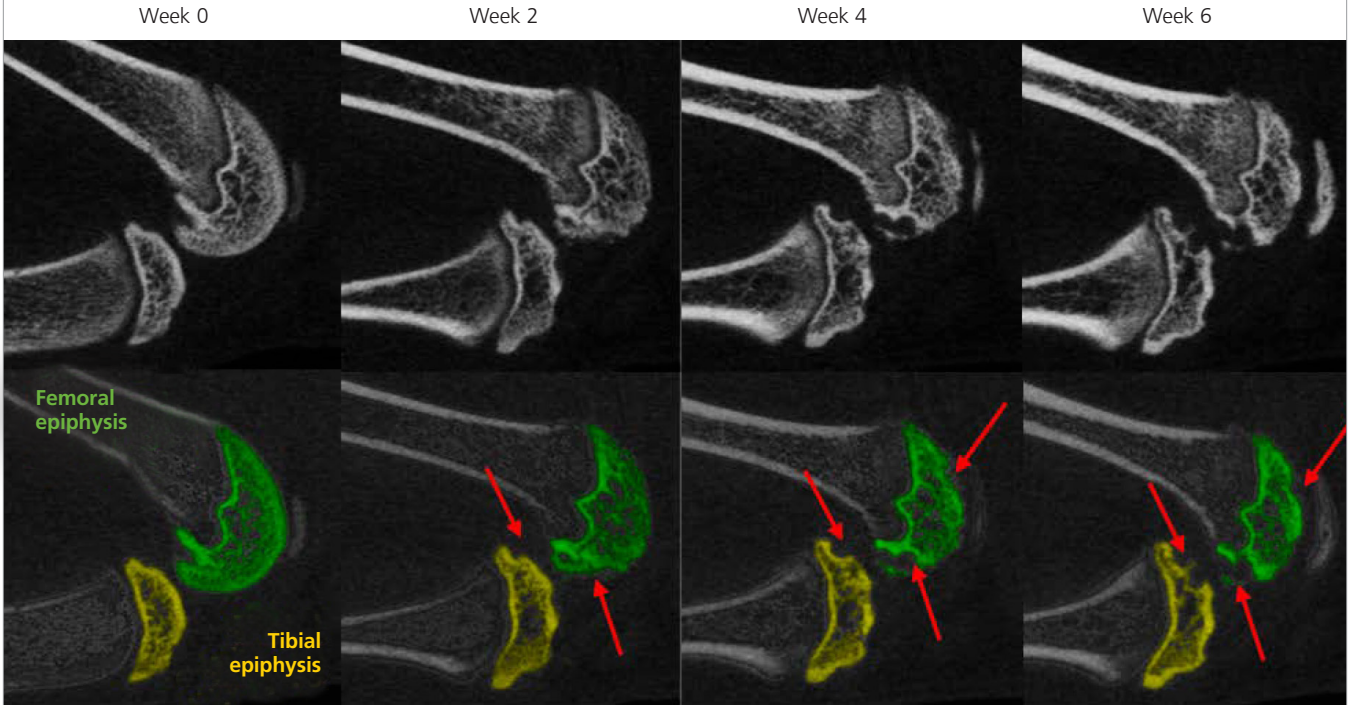


Figure 2: After MIA injection into the intra-articular space of a CD rat knee, longitudinal microCT imaging was performed bi-weekly for up to 6 weeks to non-invasively monitor knee bone erosion and destruction. The top row of images are the 2D slice views of the rat knee acquired at week 0, 2, 4 and 6. The bottom row of images are the bone segmentation results using standard visualization software, where the femoral and tibial epiphyses were marked in green and yellow respectively. Week 0 image represents the normal condition, and no damage in the knee bones was observed before MIA injection. Starting 2 weeks after MIA injection, the CT images revealed gradual bone surface erosion in both femoral (green) and tibial (yellow) epiphyses. Bone erosion (red) is clearly remarkable 6 weeks after MIA injection.

### 3D Visualization of Bone Erosion in the MIA Knees

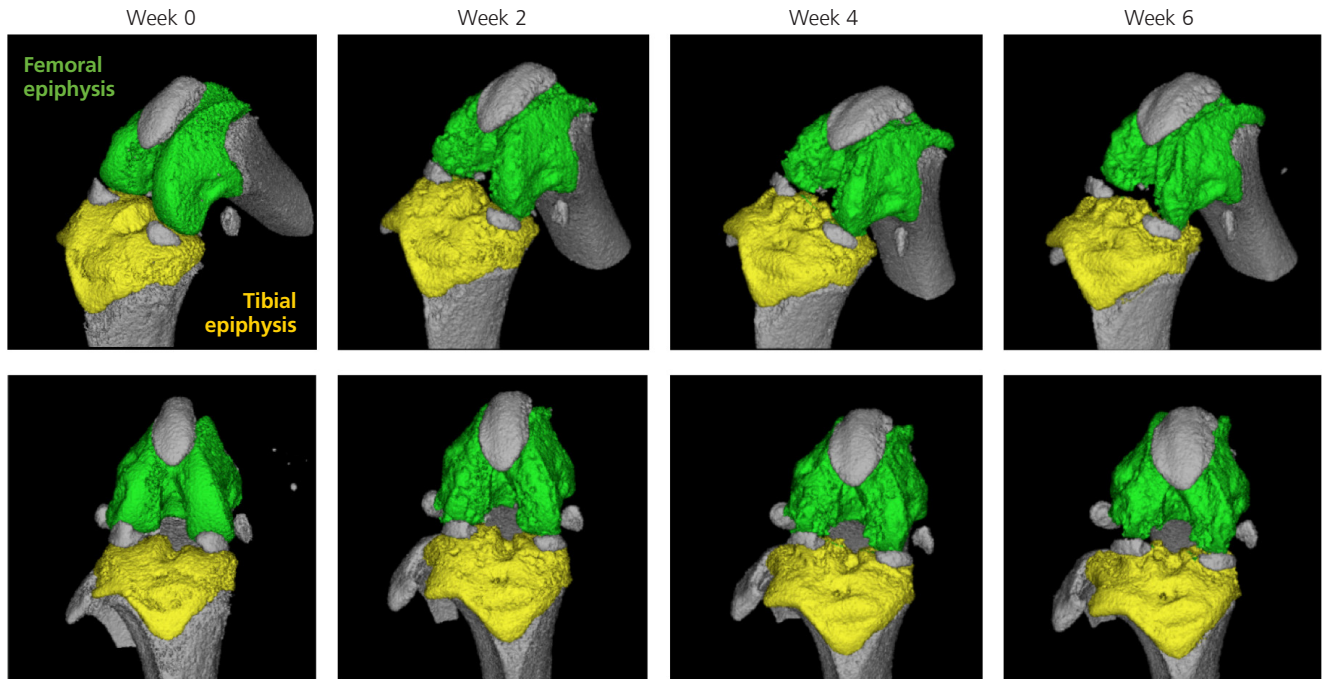


Figure 3: Bone erosion and joint destruction in MIA rat knees can be visualized in 3D using standard software. In this set of images, microCT datasets acquired at different time points after MIA injection were subjected to a manual segmentation process in order to identify the femoral (green) and tibial (yellow) epiphyses. 3D rendering of the microCT datasets clearly demonstrate bone erosion and destruction. Surface pitting was observed at the early time point (week 2), and significant deformation of the epiphyses was clearly visible at the later time point (week 6).



## Quantitative Volumetric Analysis of the 3D Objects

3D volumetric analysis was then performed in order to quantitatively measure bone erosion in the MIA OA model. Using a manual segmentation protocol, 3D objects of the femoral epiphysis was extracted throughout the course of study. In this rat OA model, femoral epiphyses show erosion and deformation as result of chronic inflammation. The 3D object view feature of the software provides researchers a useful visualization tool for direct assessment and comparison of the disease model. Figure 4A shows the extracted 3D objects of femoral epiphyses derived from Figure 3, and Figure 4B illustrates the volumetric analysis results of the study. The data clearly indicate a continuous decline in bone volume as osteoarthritis progresses, in agreement with the observed progressive surface pitting and irregularities through week 6.

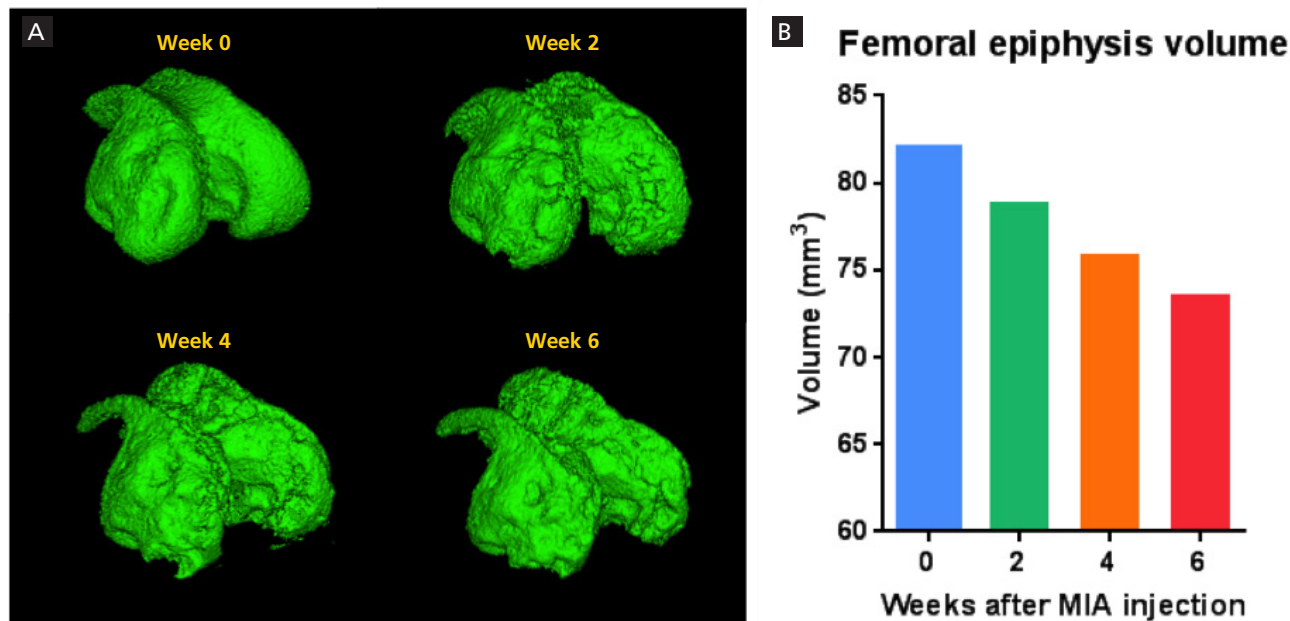
## AccuCT Advanced microCT Bone Analysis Software Automated Segmentation

The current 3D object segmentation and extraction workflow relies on manual segmentation by the user. The tool set provides several useful semi-automatic functions, such as Wall and Object Separator, to facilitate the user in identifying and extracting the 3D objects of interest. Well-trained operators can take advantage of these tools to obtain 3D objects with great precision. Nevertheless, the process requires manual review and typically

involves frame-by-frame validation and correction (if necessary) of the selected voxels. As a result, this manual segmentation process is time-consuming and is subject to human error for reproducibility.<sup>3,4,5</sup> Different operators may produce slightly different segmentation results and analyses, adding an aspect of subjectivity to the quantification.

In an effort to streamline the analysis workflow, and to improve repeatability and reproducibility, a microCT analytical tool for automatic segmentation<sup>6,7</sup> was developed. The users can instruct the software to automatically identify and extract 3D bone subjects with a few adjustments of settings, such as sensitivity and minimal voxel size, that are numerically specified to ensure true reproducibility. The new workflow in AccuCT is more efficient and can be easily standardized for training and incorporation into analysis protocols. Figure 5 outlines the general workflow using the normal week 0 microCT dataset as an example. In addition to the bones, the imported 3D image commonly contains soft tissue (muscle, fat, tendons, ligaments and organs) or small food particles in the GI tract (Figure 5A). With a simple click of a button, the AccuCT software can identify bones by filtering out soft tissue and small dense objects that do not meet the minimal voxel criteria (Figure 5B). The software then can automatically separate connected bones and generate a segmentation map by assigning a unique color to each bone fragment (Figure 5C).

### 3D Visualization of Bone Erosion in the MIA Knees



**Figure 4:** (A) 3D object rendering of the MIA femoral epiphyses at various time points using the standard analysis software. No bone erosion was observed at week 0. Starting 2 weeks after MIA injection, progressive surface erosion and eventual bone deformation were clear visible. (B) Volumetric measurements of epiphyses using the segmentation software. The MIA injection resulted in gradual bone loss as revealed by quantitative and volumetric analysis of the epiphyses in affected knees.

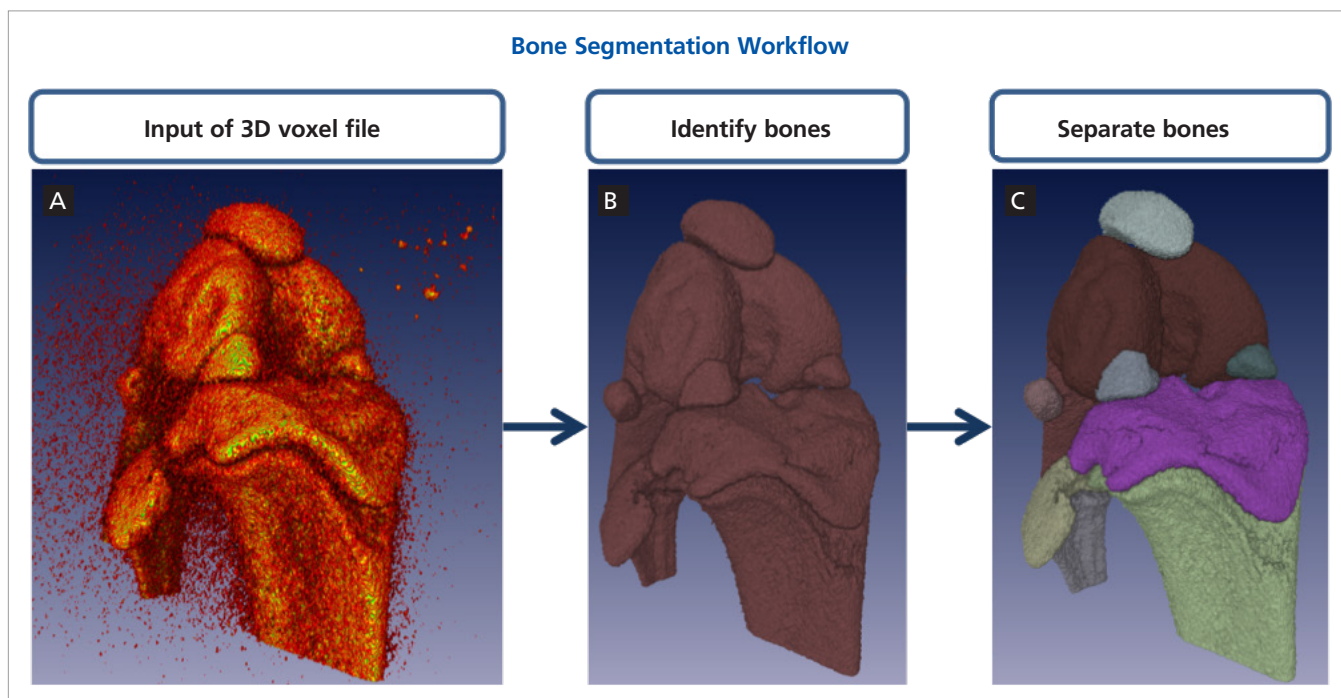


Figure 5: The microCT imaging tool can assist 3D segmentation of the bone imaging data by automatically identifying and separating bone segments in the region of interest. The general workflow involves: (A) Input of the 3D voxel data or acquired by the Quantum GX. AccuCT software can accept 3D data formats such as .vox and .dcm files. (B) The software is capable of identifying bones in the dataset and excluding objects that do not meet the selection criteria (e.g. Intensity range and minimal voxel size). (C) The software can then proceed to separate the bone segments automatically.

## Comparative 3D Segmentation

To validate the accuracy of the automated microCT imaging tool, 3D object of femoral epiphysis from a normal rat knee was masked and extracted and compared with the results generated using the manual software. Figure 6A shows the same 3D object extracted by two different software tools. Both methods produce consistent 3D objects. However, it was found that when manually performing bone segmentation, the 3D objects might contain a few errors (Figure 6A, yellow arrows) as a result of the frame-by-frame review process. AccuCT software tool removes this subjectivity and produces a more consistent and accurate 3D mask of the object. Volumetric measurements generated by the AccuCT software are in agreement with the result produced by the standard software (Figure 6B).

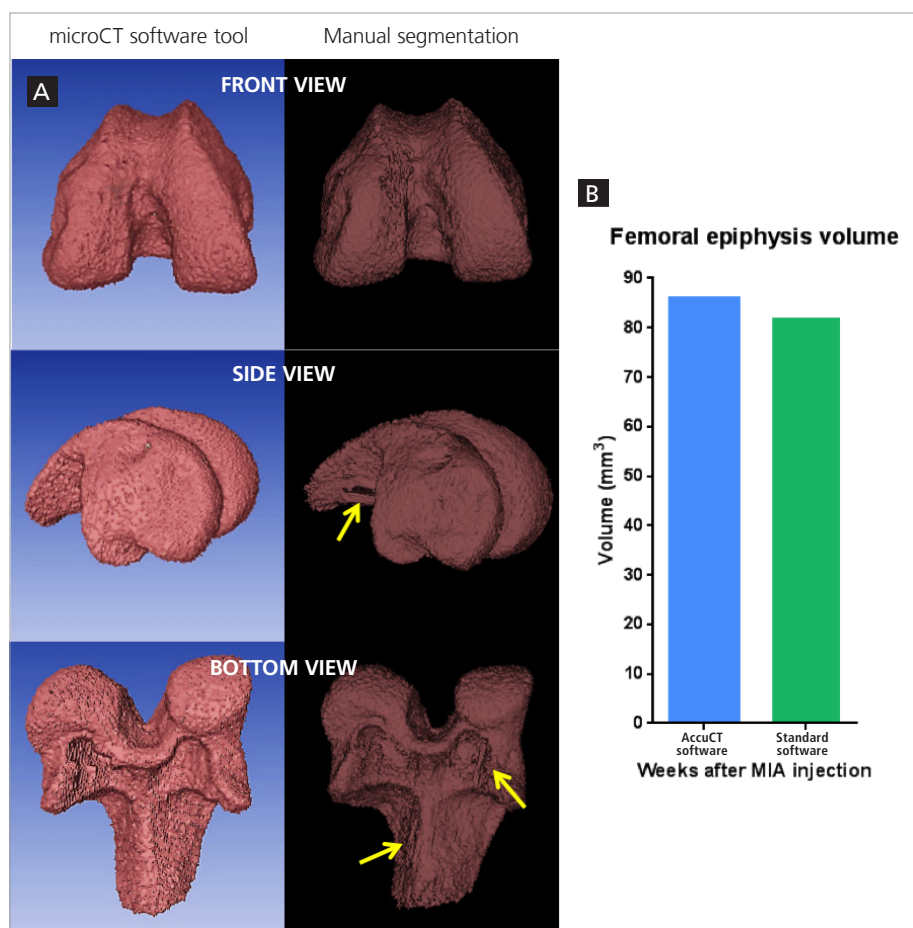


Figure 6: (A) The 3D rendering of the a normal rat femoral epiphysis using either AccuCT bone analysis visualization tool (left) or the standard software (right). (B) Quantitative comparison of the volumetric measurements of the bone using these two software tools. The yellow arrows indicate areas of incorrect 3D rendering as a result of errors introduced during the manual frame-by-frame segmentation process.

## Volumetric Measurement

Our advanced software tool can be useful for visualization and measurement of particular 3D objects in the 3D microCT dataset. To demonstrate that, the software tool was used to visually and quantitatively compare the 3D femoral epiphyses in the MIA osteoarthritis rats. The top panels of Figure 7A show the 3D rendering of the knee bones before (week 0) and after (week 6) the MIA injection, and the lower panels show the auto-segmentation results generated by the new software tool. The femoral epiphyses (red) can be easily selected and volumetrically analyzed using the built-in tools of the software. The results are consistent with the measurements obtained by the standard software (Figure 4B, Figure 7B), and both methods show a 10-11% decrease in femoral epiphysis volume by week 6.

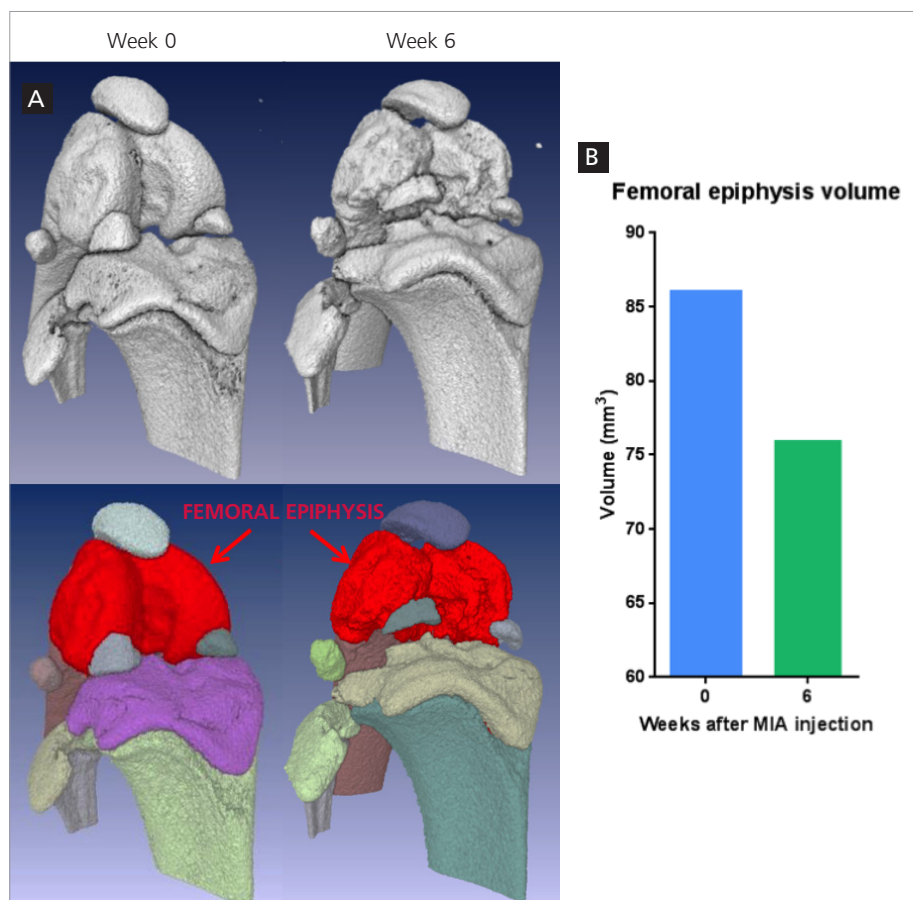


Figure 7: (A) Using the microCT imaging software tool, the 3D volumes of the femoral epiphyses in MIA rats can be extracted for volumetric measurement. Top panels show the 3D rendering of knee bones at week 0 and week 6. Lower panels show the automatic segmentation results using AccuCT software tool. The red areas indicate the femoral epiphyses in the MIA rat. (B) volumetric measurements of the bones.

## Conclusions

This Application Note provides Quantum GX users with a quick overview of its potential use for osteoarthritis research. PerkinElmer's Quantum GX microCT system is well suited to visualize bone degradation and deformation in the MIA rat osteoarthritis model. This microCT imaging system provides high-resolution images at an X-ray dose low enough for longitudinal imaging of disease progression. The sub-volume reconstruction feature further enhances image quality without introducing additional radiation dose to the animal or additional imaging time.

The standard imaging software which comes with the system has several visualization tools for bone segment identification and 3D object extraction. In addition, it provides tools for 3D volumetric analysis of bone erosion and deformation occur in this osteoarthritis model. Finally, we also demonstrate the use of AccuCT microCT bone analysis software for automated segmentation and object extraction which may greatly facilitate the analysis process. The software's automated segmentation tool reduces possible human errors during manual object masking and thus improves overall consistency and accuracy of segmentation results.

## References

1. Thakur, M., Rahman, W., Hobbs, C., Dickenson, A.H., Bennett, D.L.H. Characterisation of a peripheral neuropathic component of the rat iodoacetate model of osteoarthritis. 2012. *PLoS ONE* 7(3): e33730.
2. Janusz, M., Hookfin, E., Heitmeyer, S., Woessner, J., Freemont, A.J., Hoyland, J.A. et al. Moderation of iodoacetate-induced experimental osteoarthritis in rats by matrix metalloproteinase inhibitors. 2001. *Osteoarthritis Cartilage* 9(8):751–760.
3. Nishiyama, K.K., Campbell, G.M., Boyd, S.K. Reproducibility of bone micro-architecture measurements in rodents by *in vivo* micro-computed tomography is maximized with three-dimensional image registration. 2010. *Bone* 46(1):155-61.
4. Kohler, T., Beyeler, M., Webster, D., Muller, R. Compartmental bone morphometry in the mouse femur: reproducibility and resolution dependence of microtomographic measurements. 2005. *Calcif. Tissue Int.* 77:218-290
5. Verdelis, K., Lukashova, L., Atti, E., Mayer-Kuckuk, P., Peterson, M.G.E., Tetradis, S. et al. 2011. *Bone* 49(3):580-587.
6. Behrooz, A., Kask, P. 2015. US Patent Application No. 14/812,483.
7. Behrooz, A., Kask, P., Kempner, J., Meganck, J., Yared, W. Fully Automated Bone Detection, Segmentation, Axis Extraction, Trabecular Labeling, and ASBMR Morphometric Analysis in Small Animal Micro-computed Tomography. 2015. *American Society of Bone and Mineral Research (ASBMR) annual meeting*, Seattle, WA, USA.